

Trauma and Reconstruction

A Case of Urethrocutaneous Fistula: A Forgotten Segment of a Broken Urethral Catheter[☆]Young Kwon Hong^a, Young Dong Yu^a, Moon Hyung Kang^a, Seung Ryeol Lee^a, Dong Soo Park^a, Jong Jin Oh^{a,b,*}^a Department of Urology, CHA Bundang Medical Center, CHA University, Seongnam, Republic of Korea^b Department of Urology, Seoul National University Bundang Hospital, Seongnam, Republic of Korea

ARTICLE INFO

Article history:

Received 24 December 2013

Received in revised form

6 January 2014

Accepted 12 January 2014

Keywords:

Urethra

Foreign body

Urethral catheter

Urethrocutaneous fistula

ABSTRACT

A retained urethral catheter is a rare iatrogenic complication of which few cases have been reported in the literature. In this study, we describe a case of a forgotten urethral Foley catheter causing urethrocutaneous fistula on scrotum. An 80-year-old man was referred for a small pus-draining cutaneous opening on the lower part of the scrotum. The distal segment of a broken Foley catheter was found, and it was located from urinary bladder to bulbous urethra with its tip penetrating the urethral mucosa. This catheter was removed using flexible cystoscopic forceps, and urethrocutaneous fistula was well resolved with conservative therapy.

© 2014 The Authors. Published by Elsevier Inc. All rights reserved.

Introduction

Urinary catheterization is a useful medical practice used to drain urine from the urinary bladder in many medical conditions. However, it can cause some problems especially when it is indwelled for a long time. Complications of long-term indwelling catheters are not uncommon, such as urinary tract infections, pericatheter leakage, balloon nondeflation, encrustation by mineral salts, and stone formation.¹ However, complications associated with a forgotten segment of a broken urethral catheter have rarely been reported, and only 2 case reports are found in the literature.^{2,3} In this study, we introduce a unique case of urethrocutaneous fistula on low scrotum caused by a forgotten and amputated urethral catheter, which was safely removed with a flexible cystoscope.

Case presentation

An 80-year-old man was referred for a small pus-draining cutaneous opening on the lower part of the scrotum. The patient presented with intermittent gross painful hematuria, partial urinary retention, and dysuria. The past history showed that the patient had received urethral catheterization because of voiding difficulty 5 years before visiting our clinic. The walnut-sized mass was palpated hard in the middle of the scrotum, and pus was drained through a 2-mm-sized opening on the scrotum.

He had been treated with intravenous antibiotics and fluid for 16 days, but there was no interval improvement. Under the impression of any fistula from urethra, a retrograde urethrography (RGU) was done. When performing the RGU, we encountered a catheter shadow in the bladder and the urethra (Fig. 1). Distal tip of the catheter was lying outside of the urethral course, heading down toward the scrotum. But there was no evidence of contrast leak on RGU.

The cystoscopy was performed to confirm the catheter in the urethra (Fig. 2) and possibly to remove the catheter without open surgery. There was a Foley catheter stuck outside of the bulbous urethra. With the aid of foreign body forceps, the catheter, which was about 18F in size, could be barely grabbed and pushed back toward proximal urethra to make the buried tip of the catheter free.

[☆] This is an open-access article distributed under the terms of the Creative Commons Attribution-NonCommercial-No Derivative Works License, which permits non-commercial use, distribution, and reproduction in any medium, provided the original author and source are credited.

* Corresponding author. Tel.: +82-31-780-1836; fax: +82-31-780-5323.

E-mail address: bebsuzzang@naver.com (J.J. Oh).

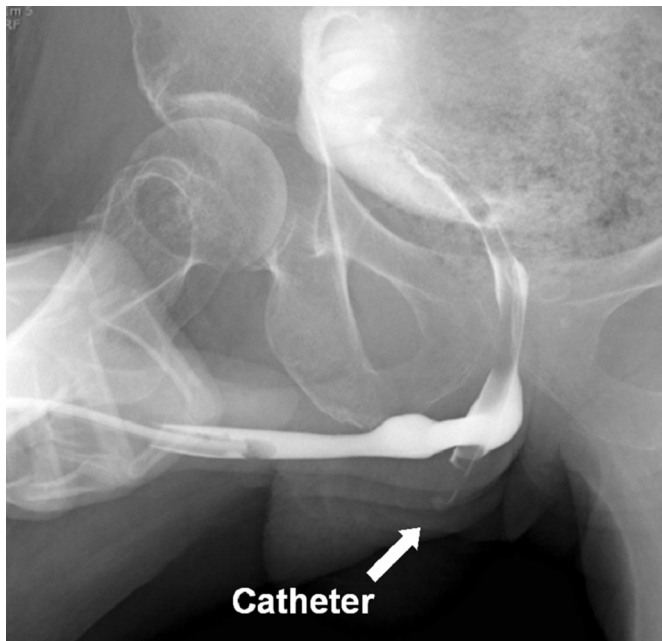


Figure 1. Retrograde urethrography shows a retained broken catheter stuck deep under the bulbous urethra.

Then it was smoothly removed out of the body along the urethral course (Fig. 3). The removed catheter was a broken one with its balloon deflated, but there was no remaining piece of catheter within the urinary bladder.

After removal of the retained catheter, the patients received further treatment with intravenous fluid and antibiotics for another 3 days. The patient was discharged home with a new urethral catheter and oral antibiotics. A week later, the fistula opening was closed spontaneously. One month later, RGU showed no leakage out

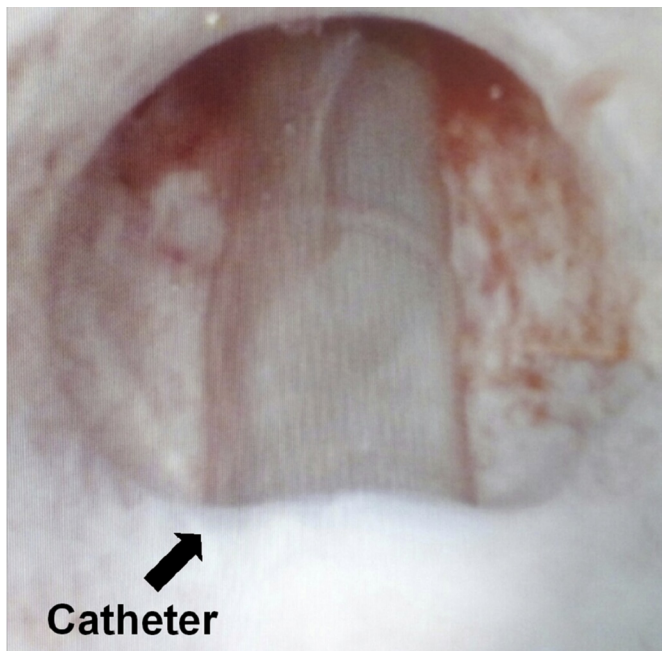


Figure 2. Urethrosopic findings: a Foley catheter with its tip penetrating the bulbous urethra at 6-o'clock direction.

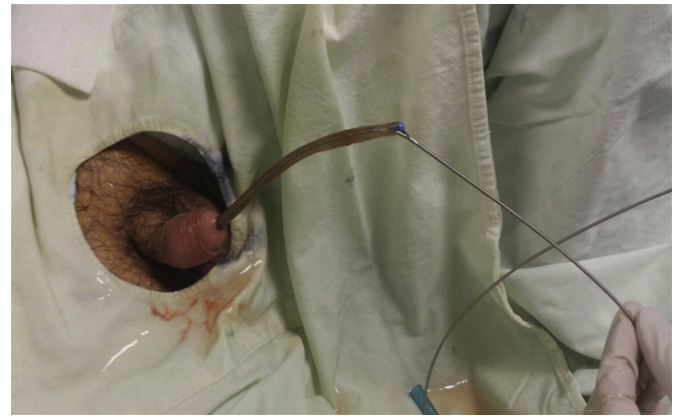


Figure 3. The tip of the broken catheter was grabbed firmly with endoscopic forceps and extracted out of the urethra.

of urethral lumen, and the scrotum returned to a normal condition without any fistulous opening or mass.

Discussion

A neglected or lost urethral catheter can result in some complications requiring surgical procedures. Bendana et al³ showed a case of a straight catheter lost in the urethra and forgotten for 20 years and its safe surgical removal. In their report, the urethral catheter with stone formation was removed through a perineal urethrotomy and incision at the meatus and fossa navicularis. In contrast to the previous report, there was no significant catheter encrustation in our case; therefore, we could remove the retained catheter via natural urethra with cystourethroscopy. However, it was reported that up to 50% of patients undergoing long-term catheterization would experience catheter encrustation, which stemmed from the infection of urease producing bacteria.^{1,4} Therefore, a neglected or lost catheter has a high probability to accompany stone formation, and surgical procedures are usually needed to remove the catheter with encrustation.

The insertion of foreign objects into the male urethra is an interesting and anecdotal event for most urologists. There is a wide variety of objects reported in the literature, and their unimaginable character makes the diagnosis and treatment as a challenge for any physician.⁵ However, a neglected or lost catheter in bladder and urethra is very rare because it might result from physician's mistake. An amputated and completely intracorporeal catheter is not shown at gross appearance so that there is a high possibility to neglect and misdiagnose. Long-term neglected catheter may result in many complications and may require surgical procedures; therefore, physicians who involve managing urinary catheters should not ignore the possible existence of remnant segment after accidental removal of the urethral catheter.

Conclusion

We encountered a very rare case of an amputated and forgotten urethral Foley catheter in urinary bladder and urethra, which resulted in urethracutaneous fistula, with its proximal tip penetrating the urethral mucosa. We successfully removed that catheter with a flexible cystoscope. Physicians who handle the urethral catheter should be aware of complications associated with neglected urethral catheters.

References

1. Liu B, Lin Y, Shen Z, Xie L. Transurethral removal of a “neglected” Foley catheter with severe encrustation: a case report. *Urolithiasis*. 2013;41:539–540.
2. Weingarten CJ, Laurain AR. Foley catheter retained for 3 years. *J Urol*. 1965;94:628–630.
3. Bendana EE, Trivedi D, Marshall J, Messing E. Lost and now found: retained straight catheter for 20 years. *Urology*. 2011;77:73–74.
4. Getliffe K. Managing recurrent urinary catheter encrustation. *Br J Community Nurs*. 2002;7:578–580.
5. Chang AY, Koh CJ, Stein JP. Urethral foreign body management: a case report. *ScientificWorldJournal*. 2004;4:56–58.