

RECONFIGURED SIGMOID COLON NEOURETHRA: SUBSTITUTION OF REFRACTORY POSTERIOR URETHRAL STRICTURE

YOUNG TAE LEE, TAEK WOO CHO, HEE SEONG JEONG, YONG KYU LEE, AND
YOUNG KWON HONG

ABSTRACT

The repair of extensive posterior urethral stricture often poses a therapeutic dilemma, especially when the urethral defect is too extensive to be repaired with traditional methods and the stricture portion has a poor blood supply. This report details the successful substitution of an extensive posterior urethral stricture using a reconfigured sigmoid colon neourethra. *UROLOGY* 65: 157–159, 2005. © 2005 Elsevier Inc.

Since Russell¹ first described the reconstructive technique for surgical treatment of urethral disease in 1914, significant advances have been made in urethral reconstructive surgery.^{2–8} However, special situations such as several failures of traditionally available urethroplasty require a more advanced approach. We report a novel surgical option using a reconfigured sigmoid colon (RSC) neourethra for the urethral substitution in the case of refractory extensive posterior urethral stricture.

MATERIAL AND METHODS

A 45-year-old man presented with recurrent extensive membranoprosthetic urethral stricture and true incontinence caused by a crushing accident at work at age 41 years. He had a small contracted bladder owing to prolonged urinary diversion using suprapubic cystostomy. Retrograde urethrography performed preoperatively revealed a long incomplete posterior urethral stricture and a previously implanted urethral stent (UroLume) (Fig. 1A). The conventional methods, including direct anastomosis, grafts, and flaps, were thought to be impossible because of the length of the urethral defect, unhealthy penile skin, and poor quality of the urethral bed caused by repeated surgery.

The operation was initiated through perineal preparation to secure a surgical space for the neourethra. The proximal and distal urethra was exposed and mobilized. The previously im-

planted UroLume was removed. Total pubectomy was performed to expand the retropubic space for mobilization of the neourethra. The urethral defect was measured at 5 cm long from the verumontanum to the bulbar urethra.

A segment of sigmoid colon 15 cm in length was harvested through a midline laparotomy under careful inspection of the arterial pulsation of a mesenteric pedicle. The resected segment of the colon was divided into two parts, consisting of 6 and 3 cm in the upper and lower segments, respectively. The mid 6 cm of the resected segment of the colon was discarded to lengthen the vascular pedicle functionally. The lower colonic segment was incised along the antimesenteric border taenia and was tailored as a hexagonally shaped colonic patch. The 3 × 5-cm colonic patch was tubularized over a 16F Foley catheter with 4-0 polyglactin suture to create the RSC neourethra (Fig. 2A). The antimesenteric border of the upper segment was incised and the anterior bladder wall opened. The appropriately tailored colonic patch of the upper segment was incorporated into the bladder with 2-0 polyglactin suture as augmentation to expand the bladder capacity, and fixation to inhibit the substituted neourethra from a return to the peritoneal cavity. End-to-end anastomosis was performed between the normal urethra and the RSC neourethra with 4-0 polyglactin suture (Fig. 2B). A suprapubic tube was placed for urinary diversion and a drainage tube was placed in the retropubic space. The patient was transferred to the rehabilitation medicine department for physical therapy 2 months postoperatively.

At last follow-up, 15 months postoperatively, the patient underwent retrograde urethrography, voiding cystourethrography, uroflowmetry, and cystourethroscopy. Retrograde urethrography did not reveal any narrowing of the lumen of the substituted neourethra (Fig. 1B). Voiding cystourethrography demonstrated restored urinary drainage and an irregular neourethral lumen. Uroflowmetry showed a urinary peak flow of 18.9 mL/s and a voided urine volume of 330 mL. A corrugated, viable neourethra with an adequate lumen was observed during cystourethroscopy. Bowel-related complications were not detected after laparotomy. True incontinence, mild postvoid dribbling, intermittent hesitancy, abdominal strain, and small amounts of mucus

From the Department of Urology, Bundang CHA Hospital, Pochon CHA University College of Medicine, Sungnam, Korea

Reprint requests: Young Tae Lee, M.D., Department of Urology, Bundang CHA Hospital, Pochon CHA University College of Medicine, 351 Yatap-dong Bundang-gu, Sungnam-si, Kyonggi-do 463-712, Republic of Korea. E-mail: ytleeuro@cha.ac.kr

Submitted: June 7, 2004, accepted (with revisions): August 16, 2004

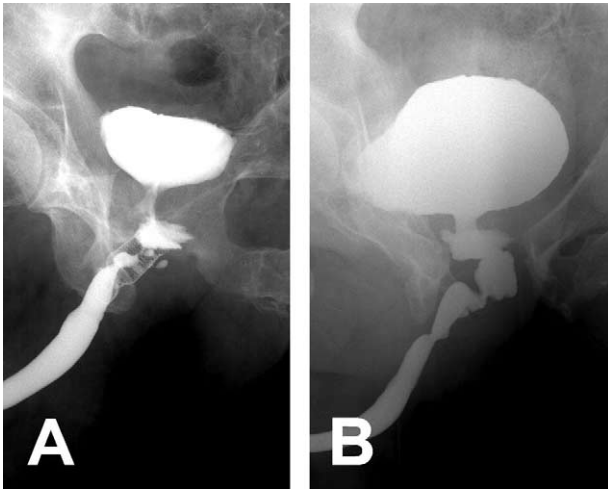


FIGURE 1. (A) Preoperative retrograde urethrography showed long stricture of posterior urethra with implanted urethral stent (UroLume). (B) Postoperative retrograde urethrography revealed the restored posterior urethra with tortuous, dilated neourethral lumen.

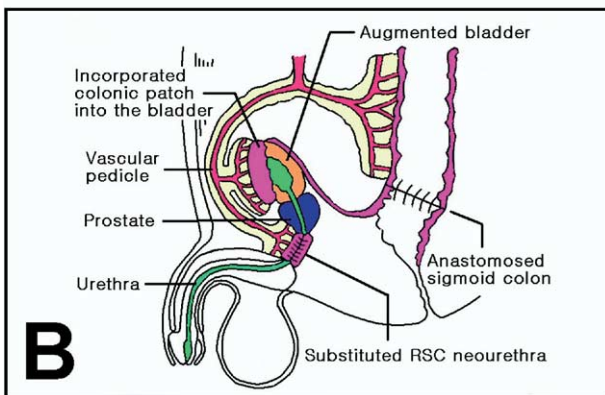
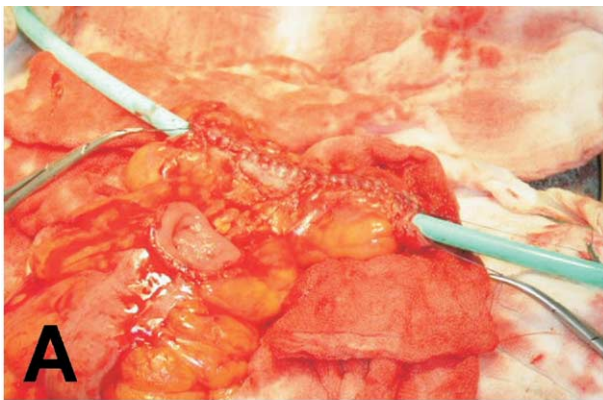


FIGURE 2. (A) Tubularization of colonic patch over 16F Foley catheter for RSC neourethra. (B) Schematic diagram of urethral substitution using RSC neourethra.

production creating urethral discharge were the urinary symptoms observed at the last follow-up.

COMMENT

Many surgical techniques have been developed to restore urethral continuity and establish a

normal lumen. In particular, two novel techniques to urethral reconstruction have recently been reported by Bales *et al.*⁹ and Xu *et al.*¹⁰

Bales *et al.*⁹ used tailored jejunal free tissue transfer to reconstruct a complex anterior urethral stricture. A successful postoperative result was reported. However, the technique requires surgical experience and expertise with microvascular anastomosis, which is not familiar to most urologic surgeons. Xu *et al.*¹⁰ reported one-stage urethral reconstruction using a colonic mucosa graft for the treatment of a long complex anterior urethral stricture. This technique is not universally applicable to all patients because the graft requires intimate contact with a well-vascularized recipient bed, which is not present in all patients.

To our knowledge, we present the first case using the RSC neourethra for urethral reconstruction. This approach gives two obvious benefits—the easy availability of the intestine and less need for a well-vascularized urethral bed. The intestinal manipulation has been familiar to urologists in the form of augmentation cystoplasty, sigmoid conduit, and colonic bladder substitution. The advantages of using the sigmoid colon are its anatomic location in the pelvis and the simplicity of the urethral anastomosis. Furthermore, the loss of parts of the sigmoid colon has very little, if any, impact on bowel function.¹¹ Because it is a kind of sigmoid colon flap, it matters little that the patient has a poor urethral bed from multiple operations or severe trauma.

Some problems may arise with this technique. Patients must undergo laparotomy to harvest the intestinal segment and that may cause morbidity such as prolonged ileus, fistula, intestinal obstruction, or adhesions.^{12,13} Total pubectomy may put limitations on leg movement, by which a muscular compartment takes charge of the internal rotation and adduction of the legs loses its origin site. An expanded dead space owing to the perineal preparation may induce the neourethra to become sacculated if the dead space is not filled appropriately with a mesenteric fat or muscle flap. This technique also requires a long operating time, which gives severe stress to patients owing to the lengthy period of anesthesia.

CONCLUSIONS

We present a novel solution for reconstructive urologists when treating refractory urethral stricture. The principle of using the RSC neourethra is potentially widely applicable to all patients with significant urethral disease, regardless of the diseased site or its extent. The results of 15 months of follow-up were satisfactory, but longer follow-up is required to monitor for possible future problems

such as recurrent urethral stricture, stone formation, and metabolic complications. Additional experiences may explicate a surgical indication for our method and reduce the postoperative complications and operation time to a minimum.

REFERENCES

1. Russell RH: The treatment of urethral stricture by excision. *Br J Surg* 2: 375–375, 1914.
2. Fernandes M, and Draper JW: Two-stage urethroplasty. Improved method for treating bulbomembranous strictures. *Urology* 6: 568–575, 1975.
3. Webster GD, Koefoot RB, and Sihelnik SA: Urethroplasty management in 100 cases of urethral stricture: a rationale for procedure selection. *J Urol* 134: 892–898, 1985.
4. Ransley PG, Duffy PG, Oesch IL, *et al*: The use of bladder mucosa and combined bladder mucosa/preputial skin grafts for urethral reconstruction. *J Urol* 138: 1096–1098, 1987.
5. Caldamone AA, Edstrom LE, Koyle MA, *et al*: Buccal mucosal grafts for urethral reconstruction. *Urology* 51(suppl 5A): 15–19, 1998.
6. McAninch JW, and Morey AF: Penile circular fasciocutaneous skin flap in 1-stage reconstruction of complex anterior urethral strictures. *J Urol* 159: 1209–1213, 1998.
7. Khazanchi RK, Dorairajan LN, Dogra PN, *et al*: Free-flap urethroplasty for a complex, long-segment stricture of the bulbomembranous urethra. *J Reconstr Microsurg* 14: 223–225, 1998.
8. Koshima I, Inagawa K, Okuyama N, *et al*: Free vascularized appendix transfer for reconstruction of penile urethras with severe fibrosis. *Plast Reconstr Surg* 103: 964–969, 1999.
9. Bales GT, Kuznetsov DD, Kim HL, *et al*: Urethral substitution using an intestinal free flap: a novel approach. *J Urol* 168: 182–184, 2002.
10. Xu YM, Qiao Y, Sa YL, *et al*: 1-Stage urethral reconstruction using colonic mucosa graft for the treatment of a long complex urethral stricture. *J Urol* 171: 220–223, 2004.
11. Shekarriz B, Upadhyay J, Demirbilek S, *et al*: Surgical complications of bladder augmentation: comparison between various enterocystoplasties in 133 patients. *Urology* 55: 123–128, 2000.
12. Hendren WH, and Hendren RB: Bladder augmentation: experience with 129 children and young adults. *J Urol* 144: 445–453, 1990.
13. Kilic N, Celayir S, Elicevik M, *et al*: Bladder augmentation: urodynamic findings and clinical outcome in different augmentation techniques. *Eur J Pediatr Surg* 9: 29–32, 1999.